

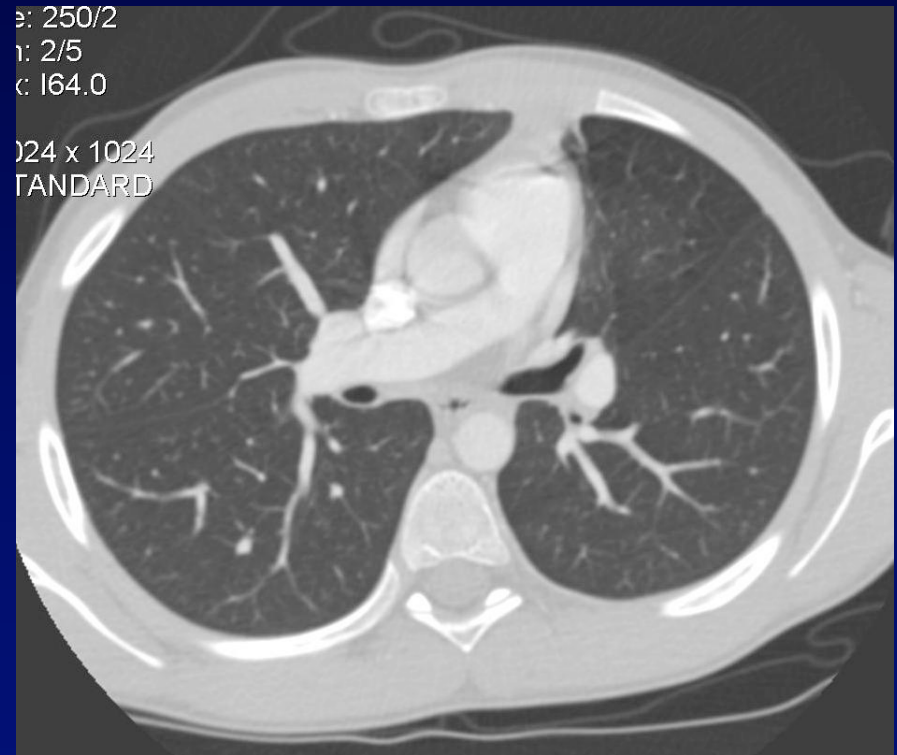
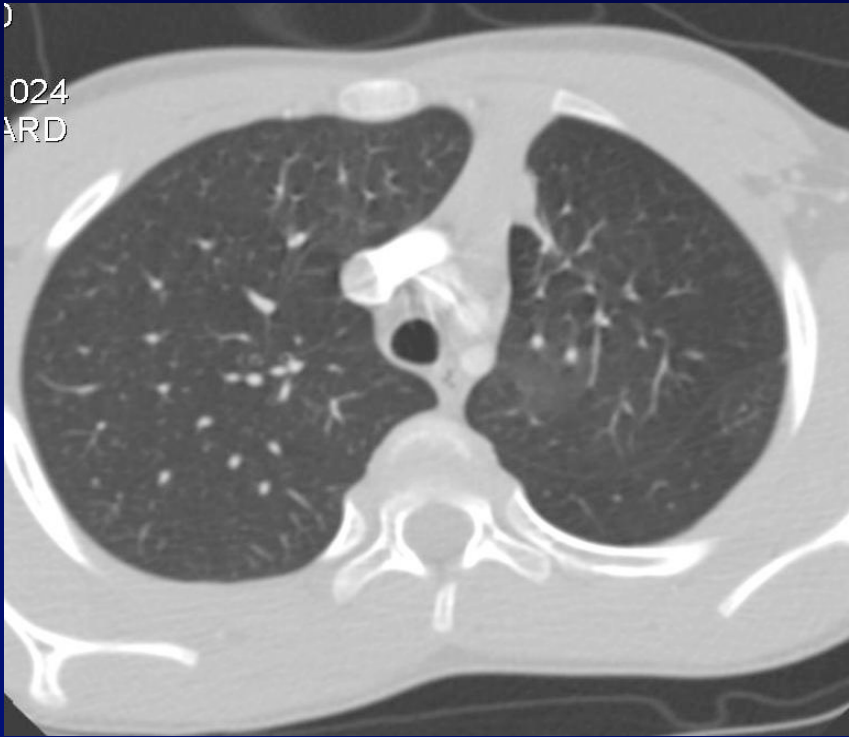


G.DURAND J.GIRON P.FAJADET

Garçon de 10 ans

Dyspnée,

Passé « infantile » ...



INSPI

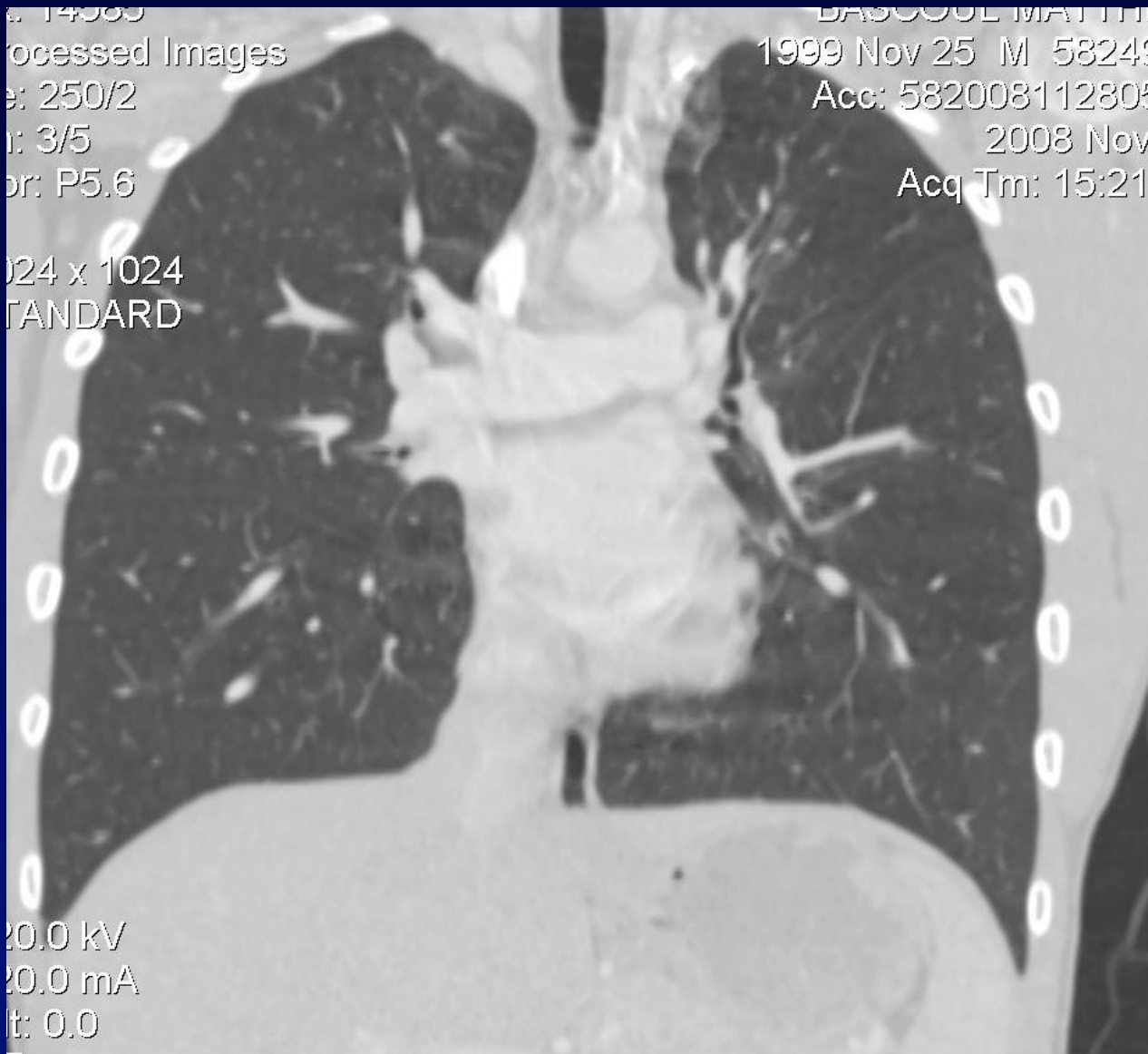

14380  
Processed Images  
e: 250/2  
r: 3/5  
or: P5.6

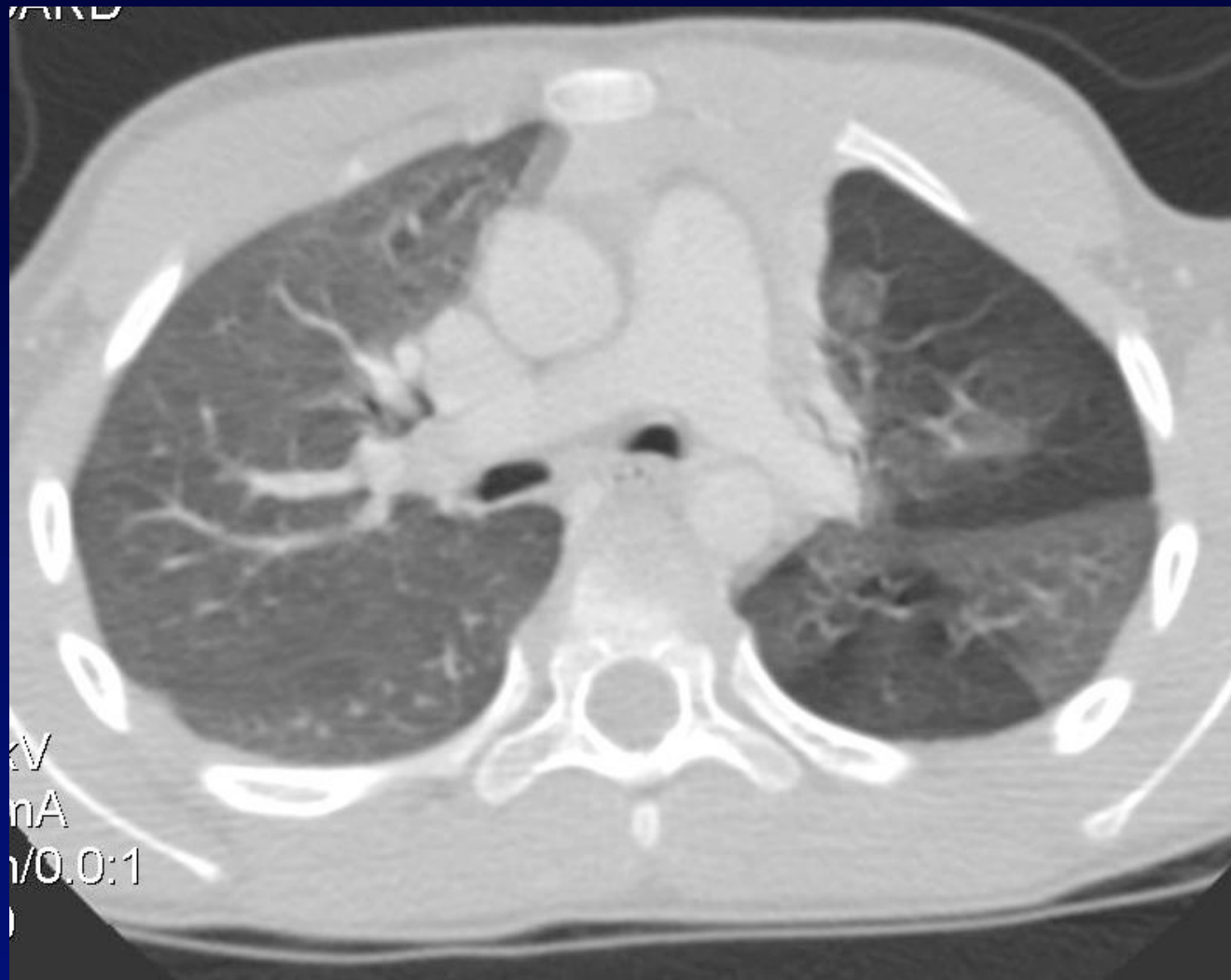
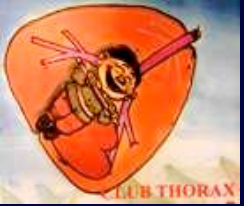BASCONE MATTHEW  
1999 Nov 25 M 58249  
Acc: 582008112805  
2008 Nov  
Acq Tm: 15:21

1024 x 1024  
STANDARD

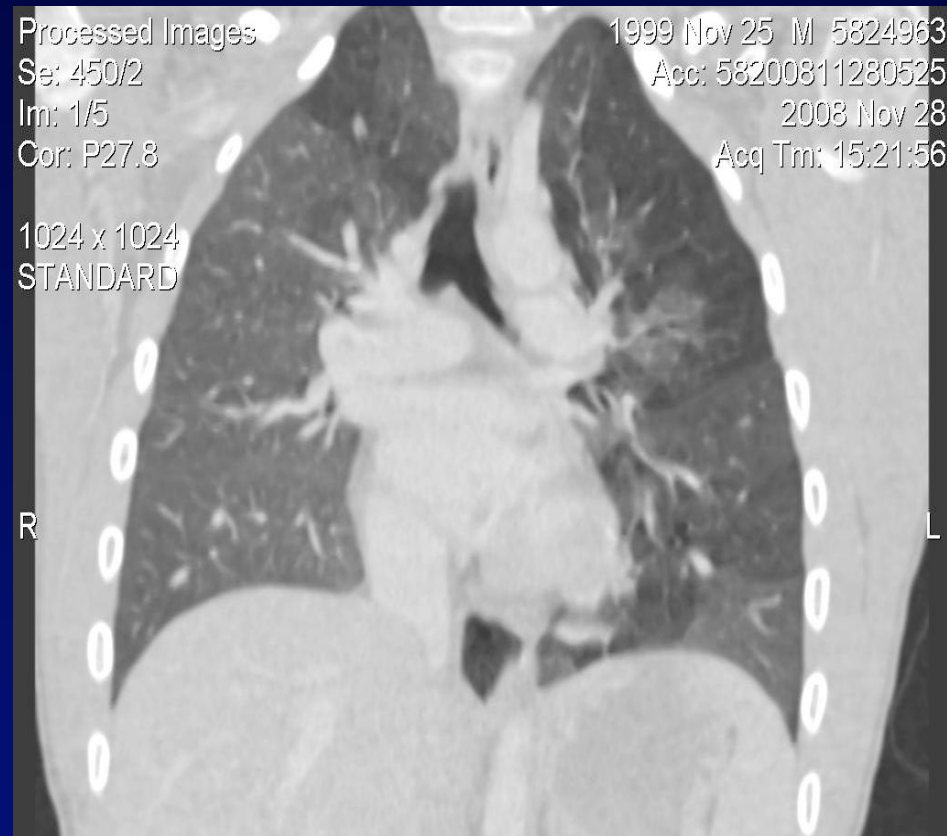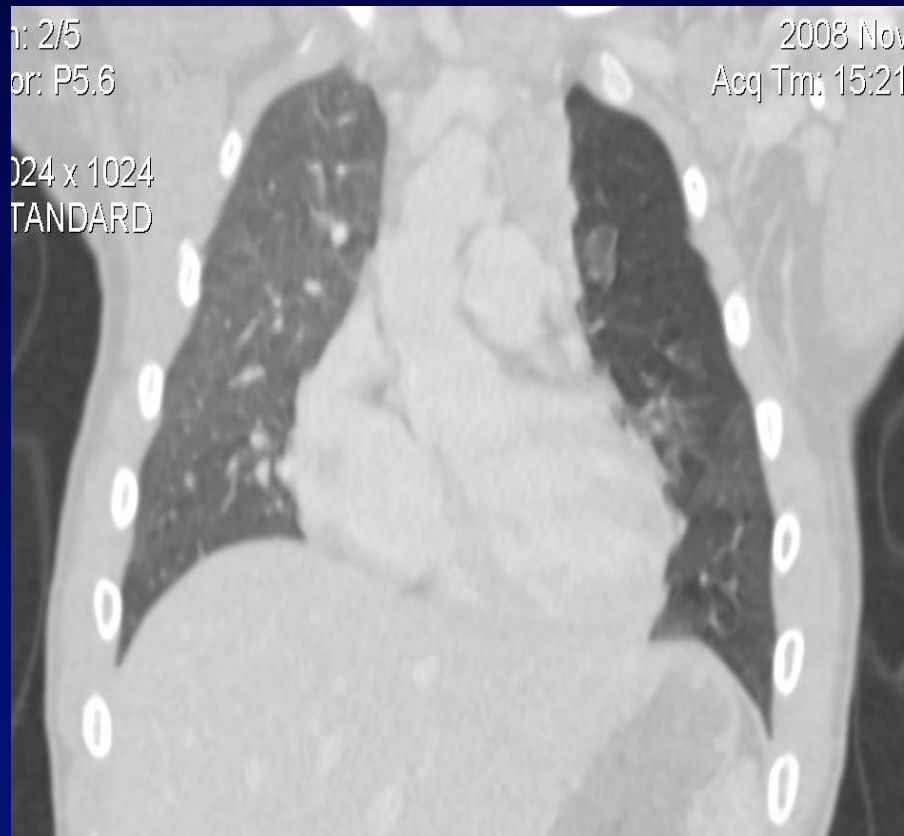20.0 kV  
20.0 mA  
t: 0.0



Reconstruction INSPI



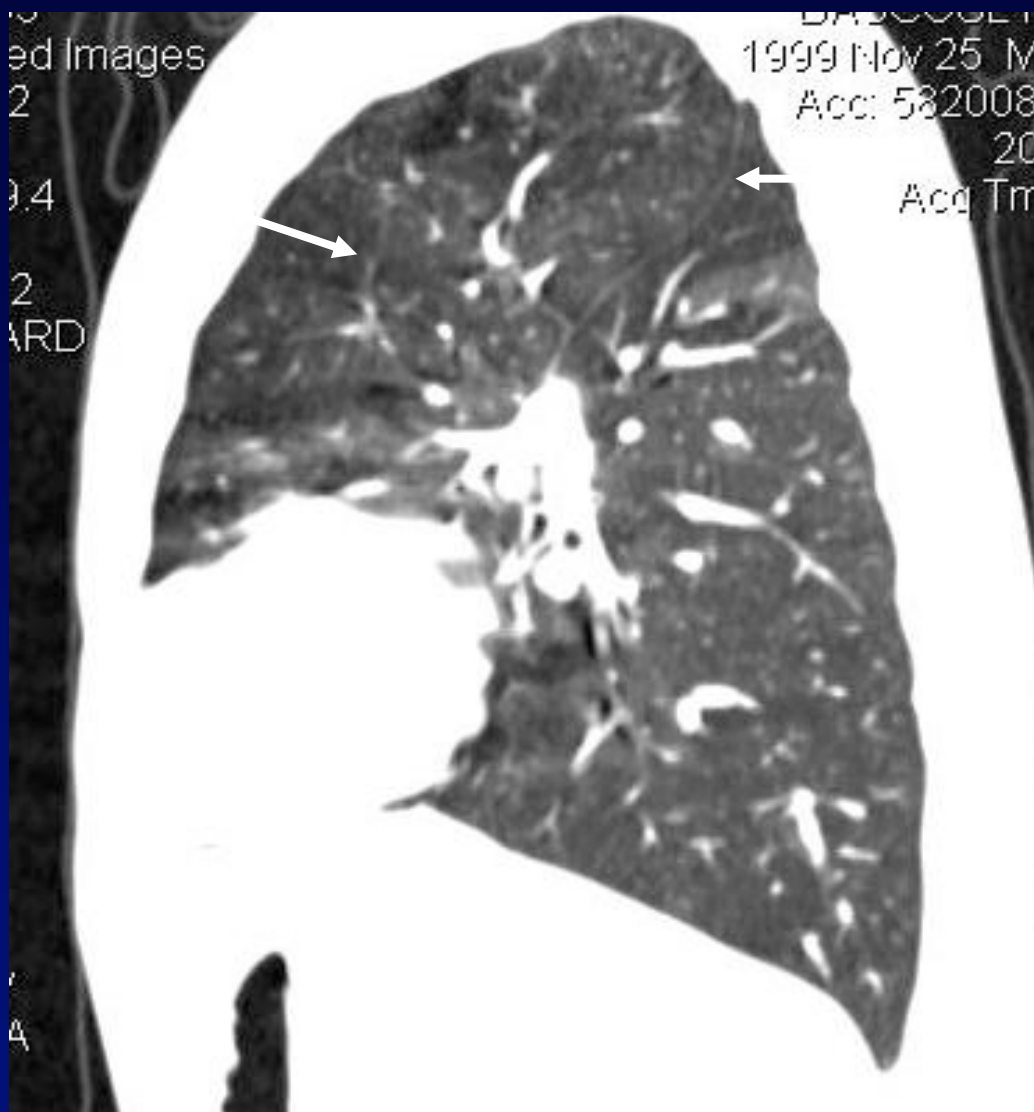Coupe en EXPI



# Reconstructions en EXPI



Diagnostic ?



EXPI



Diagnostic

Syndrome de Mac Leod



# Séquelles de Bronchiolites de l'enfance

Uni pulmonaire ou non

Importance des clichés en EXPI